

Viral Croup

Amisha Malhotra, MD,*
and Leonard R. Krilov,
MD†

Objectives After completing this article, readers should be able to:

1. Clarify the definition and terminology of viral croup.
2. List the etiologic agents associated with viral croup.
3. Describe the pathogenesis of viral croup.
4. Delineate the clinical signs and symptoms associated with viral croup.
5. Differentiate epiglottitis from viral croup.
6. Discuss the identification and management of viral croup.

Introduction

Croup is a common respiratory illness in children. The word croup is derived from the Anglo-Saxon word *kropan*, which means “to cry aloud.” The illness commonly is manifested in young children by a hoarse voice; dry, barking cough; inspiratory stridor; and a variable amount of respiratory distress that develops over a brief period of time.

Definition and Terminology

The term “croup syndrome” refers to a group of diseases that varies in anatomic involvement and etiologic agents and includes laryngotracheitis, spasmodic croup, bacterial tracheitis, laryngotracheobronchitis, and laryngotracheobronchopneumonitis. Although the terms “laryngotracheitis” and “laryngotracheobronchitis” frequently are used interchangeably in the literature, they represent two different disease states. The most common and most typical form of the viral croup syndrome is acute laryngotracheitis, which involves obstruction of the upper airway in the area of the larynx, infraglottic tissues, and trachea and is due to an infectious agent. The lung parenchyma is involved occasionally. Among the noninfectious etiologies of this syndrome are foreign body aspiration, trauma (eg, due to intubation), and allergic reaction (eg, acute angioneurotic edema).

Acute viral infection is the most common cause of croup, but bacterial and atypical agents also have been identified. It generally is accepted that acute laryngotracheitis and spasmodic croup are caused by viral agents alone, whereas both bacterial and viral agents may be responsible for causing disease further down the respiratory tract, such as laryngotracheobronchitis and laryngotracheobronchopneumonitis. Bacterial tracheitis, also known as membranous or bacterial croup, involves infection with bacteria such as *Staphylococcus aureus*, *Haemophilus influenzae*, and *Corynebacterium diphtheriae* and will not be discussed further in this review.

Epidemiology

Croup accounts for more than 15% of respiratory tract disease seen in pediatric practice. Viral croup is primarily a disease of children between 1 and 6 years of age, with a mean age of 18 months. In the United States, its peak incidence is about 5 cases per 100 children during the second year of life. Although most cases occur during the late fall and winter, croup can manifest throughout the year. It is more common in boys than in girls.

Etiology

Parainfluenza viruses (types 1, 2, and 3) account for more than 65% of croup cases, with parainfluenza virus types 1 and 2 responsible for the majority of illnesses and outbreaks

*Division of Pediatric Infectious Diseases, UMDNJ–Robert Wood Johnson School of Medicine, New Brunswick, NJ.

†Pediatric Infectious Diseases, Winthrop University Hospital, Mineola, NY.

Table 1. Etiologic Agents in the Croup Syndrome and Their Role in Frequency and Severity of Disease

Disease	Etiologic Agent	Frequency Associated With Disease	Severity of Disease
Laryngotracheitis and Spasmodic Croup	Parainfluenza viruses	Most frequent	Mild to severe
	Influenza viruses A, B	Occasional to frequent	Variable; most severe cases associated with influenza A
	Respiratory syncytial virus	Occasional	Mild to moderate
	Adenovirus	Occasional	Mild to moderate
	Measles	Occasional	Moderate to severe
Laryngotracheobronchitis and Laryngotracheo-bronchopneumonitis	Parainfluenza viruses	Rare	Severe
	Influenza viruses A, B	Rare	Severe
	<i>Staphylococcus aureus</i> <i>Streptococcus pyogenes</i> <i>S pneumoniae</i> <i>Haemophilus influenzae</i>	More common	Most severe
	Other bacteria (eg, <i>Moraxella catarrhalis</i>)	Rare	Moderate to severe

Adapted from Cherry JD. Croup. In: Feigin RD, Cherry JD eds. *Textbook of Pediatric Infectious Diseases*. 4th ed. Philadelphia, Pa: WB Saunders; 1998:228–241.

(Table 1). Other viruses associated with this disease include influenza A and B, adenovirus, respiratory syncytial virus (RSV), and measles. The most severe laryngotracheitis has been noted in association with influenza A viral infections. *Mycoplasma pneumoniae* has been isolated from children who have croup, albeit rarely, and causes mild disease.

Bacterial causes of croup have been identified, specifically in laryngotracheobronchitis and laryngotracheo-bronchopneumonitis. Secondary bacterial superinfection of viral disease is the ultimate cause. Bacteria that have been implicated include *Streptococcus pyogenes*, *S pneumoniae*, *Staphylococcus aureus*, *Haemophilus influenzae*, and *Moraxella catarrhalis*.

Pathogenesis

As with most respiratory infections, viral infection in acute laryngotracheitis, laryngotracheobronchitis, and laryngotracheobronchopneumonitis begins in the nasopharynx and spreads to the respiratory epithelium of the larynx and trachea where it may halt or proceed further down the respiratory tree. Diffuse inflammation, erythema, and edema develop in the tracheal walls, and the mobility of the vocal cords becomes impaired. The portion of the trachea below the larynx (subglottic trachea)

is the narrowest part of a child's upper airway. This area is surrounded by firm cartilage, and any swelling in that region encroaches on the airway and can restrict airflow significantly. This airway narrowing leads to audible inspiratory stridor, and the vocal cord swelling results in a hoarse voice.

With disease progression, the tracheal lumen becomes further obstructed by fibrinous exudate and pseudomembranes. Histologic sections of the larynx and trachea reveal marked edema, with cellular infiltration of histiocytes, lymphocytes, plasma cells, and polymorphonuclear leukocytes.

Further extension of the disease from the trachea into the bronchi and alveoli results in laryngotracheobronchitis and laryngotracheobronchopneumonitis, respectively. However, the progressive obstructive disease at this level is usually the result of secondary bacterial involvement.

In spasmodic croup, histology of the subglottic tissues shows noninflammatory edema. Accordingly, it is presumed that there is no direct viral involvement of the tracheal epithelium in this entity and that the obstruction is due to the sudden occurrence of noninflammatory edema within the submucosa of the subglottic trachea. Although there is an association with the same viruses

Table 2. Commonly Observed Features in Differential Diagnoses of Infectious Upper Airway Obstruction

Feature	Acute Laryngotracheitis	Laryngotracheobronchitis/Pneumonitis	Spasmodic Croup	Epiglottitis
Prodrome	Upper respiratory symptoms	Upper respiratory symptoms	None or minimal coryza	None or mild upper respiratory infection symptoms
Age	3 mo to 3 y	3 mo to 8 y	3 mo to 3 y	1 y to 8 y
Onset	Gradual (12 h to 48 h)	Variable (12 h to 7 d)	Sudden, at night	Rapid (4 h to 12 h)
Fever	Variable	Unusually high	No	High
Hoarseness, barking cough	Yes	Yes	Yes	No
Inspiratory stridor	Yes; minimal to severe	Yes; usually severe	Yes; usually moderate	Yes; moderate to severe
Dysphagia	No	No	No	Yes
Toxic appearance	No	Yes	No	Yes
Etiology	Viral infection	Viral infection with bacterial superinfection	Viral infection with allergic component	Bacterial infection with positive throat and blood cultures

that cause acute laryngotracheitis, the reason for this sudden edema is unknown. It has been suggested that spasmodic croup represents more of an allergic reaction to viral antigens than direct infection.

Clinical Presentation

Acute Laryngotracheitis

Acute laryngotracheitis typically starts with rhinorrhea, pharyngitis, and low-grade fever of a few days' duration (Table 2). Mild cough also is frequent. However, after a short period, usually 12 to 48 hours, upper airway obstructive signs and symptoms are noted. The child develops a characteristic "barking" cough, hoarseness, and inspiratory stridor, with or without fever.

Physical examination reveals a child who has a hoarse voice, coryza, a normal or mildly inflamed pharynx, and a slightly increased respiratory rate. The speed of progression and degree of respiratory distress can vary substantially. Most cases are characterized by only the hoarseness and barking cough, with no other evidence of airway obstruction. These symptoms gradually normalize within 3 to 7 days. In other cases, an increasing severity of obstruction is evident and accompanied by increasing heart and respiratory rates, flaring of alar nasi, and cyanosis with supra- and infraclavicular and sternal retractions. Affected children become restless and anxious with

the development of progressive hypoxia and require close monitoring. The duration of illness in more severely affected children usually is 7 to 14 days.

Laboratory studies are only minimally useful in acute laryngotracheitis and are not performed routinely because the diagnosis is made clinically. When performed, the white blood cell count frequently is elevated above $10 \times 10^9/\text{L}$ ($10,000/\text{cu mm}$), and polymorphonuclear cells predominate. Very high white blood cell counts ($>20 \times 10^9/\text{L}$ [$20,000/\text{cu mm}$]) with band forms suggest bacterial superinfection or a different diagnosis, such as epiglottitis. Anterior chest radiographs may reveal subglottic narrowing.

Laryngotracheobronchitis and Laryngotracheobronchopneumonitis

Laryngotracheobronchitis and laryngotracheobronchopneumonitis are far less common than acute laryngotracheitis and spasmodic croup. These first two illnesses can be considered extensions of acute laryngotracheitis. Initially, the child presents with signs and symptoms of laryngotracheitis, with mild-to-moderate disease for the first 5 to 7 days that suddenly progresses to severe disease. The severity of infection is due to bacterial superinfection and is signaled by a sudden worsening of clinical signs and symptoms, including new onset of fever

(usually high-grade) and an increase in the work of breathing.

On presentation, the child appears toxic and highly febrile and has signs and symptoms of both upper and lower airway obstruction. An increased respiratory rate, rales, wheezing, and air trapping are noted. Chest radiographs may reveal pulmonary infiltrates. Airway obstruction usually requires intubation or a tracheostomy. Several instances of laryngotracheobronchitis/laryngotracheobronchopneumonitis associated with toxic shock syndrome have been noted.

Spasmodic Croup

Spasmodic croup tends to occur at night in young children between 3 months and 3 years of age. Often, it is difficult at the onset to distinguish laryngotracheitis from spasmodic croup. The child may have cold symptoms and look otherwise well. Initially, the child awakens at night with sudden dyspnea, croupy cough, and inspiratory stridor. Fever is not present, and gentle reassurance and administration of moist air provide relief. The symptoms are the result of sudden subglottic edema, and the child can have repeat attacks on the same night and for the next three or four successive nights. Spasmodic croup may be differentiated from laryngotracheitis with endoscopic examination. The laryngeal mucosa appears pale and boggy in spasmodic croup and erythematous and inflamed in acute laryngotracheitis.

Differential Diagnosis

The most frequent serious differential diagnostic problem has been distinguishing acute epiglottitis from acute laryngotracheitis. Ascertaining the child's immunization history is vital. Since the introduction of the *H influenzae* type b vaccine in 1990 in the United States, cases of epiglottitis have declined markedly. However, because organisms other than *H influenzae* occasionally can cause epiglottitis, this diagnosis cannot be forgotten.

In acute epiglottitis, the important differential points on clinical examination are lack of a croupy cough, drooling, toxic appearance, growing anxiety and apprehension, a sitting posture with the chin pushed forward and refusal to lie down, and on inspection, the presence of a cherry-red epiglottis. In contrast, the child who has acute laryngotracheitis will have a barking cough, be comfortable supine, and be less apprehensive. On visual inspection, the epiglottis appears normal. Lateral neck and chest radiographs have been used to help make the diagnosis, but they usually are not recommended when epiglottitis is suspected because of the tenuous condition of these patients. When epiglottitis is suspected, the

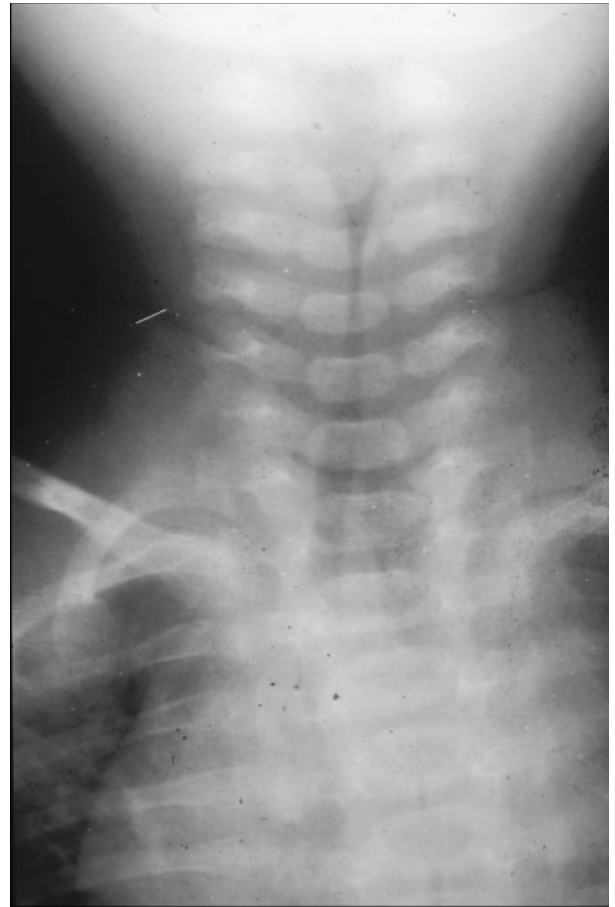

Figure 1. Tapered subglottic narrowing of the airway on radiography, demonstrating the classic "steeple sign" in croup. (Courtesy of Dr Jack Levenbrown, Manhasset, NY.)

clinician must avoid agitating the patient, which could aggravate the child's already compromised respiratory state, and should have preparations for intubation readily available. Classic radiographs of a child who has laryngotracheitis show the characteristic "steeple sign" or airway narrowing in the subglottic area; in epiglottitis, these films classically demonstrate the "thumb sign" of the swollen epiglottis (Figs. 1 and 2). Radiographs, if performed, should be used as an adjunct to help confirm the diagnosis; visual inspection of the epiglottis and clinical correlation are keys to diagnosis.

Other diagnoses for a child presenting with acute upper airway obstruction include foreign body aspiration and angioneurotic edema. Acute angioneurotic edema usually presents with other evidence of swelling of the face and neck. Laryngeal diphtheria, although rare these days, should be considered. Important information in this regard is the immunization history, clinical evidence

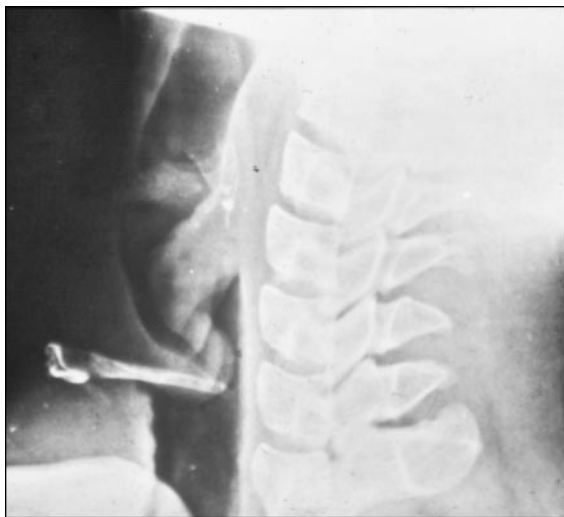


Figure 2. Lateral neck radiograph demonstrating the classic "thumb sign" seen in epiglottitis.

of pharyngeal involvement, greater degree of hoarseness, and relative slowness of disease progression. Other conditions to consider include retropharyngeal or peritonsillar abscess, subglottic stenosis, infectious mononucleosis, bacterial tracheitis, and paraquat poisoning.

Diagnosis

Croup is diagnosed primarily on clinical grounds, although diagnostic aids have been used in support of the initial diagnosis.

Plain films of the neck may show the classic radiologic steeple sign, with a narrowed air column in the subglottic area seen on a posteroanterior view (Fig. 1). The hypopharynx may be overdistended in the lateral view. These findings are present in only 50% of cases of croup; many children who have croup have normal findings on radiography. Furthermore, the steeple sign frequently is present in radiographs obtained from children who do not have croup, depending on the phase of respiration. Therefore, because radiographic findings do not correlate well with clinical measures of disease severity, these studies should be limited to children whose illness is atypical and whose respiratory status is stable because any unnecessary manipulation of the child can aggravate symptoms.

Because laryngotracheitis is a disease of the upper airway, alveolar gas exchange usually is normal, and hypoxia and low oxygen saturation will be undetectable until a patient's condition is severe. Most children who have laryngotracheitis or spasmodic croup have normal findings on pulse oximetry. Serial observations and fre-

quent physical examinations remain the most accurate methods of monitoring a child who has acute laryngotracheitis. Pulse oximetry may be more useful in patients who have laryngotracheobronchitis or laryngotracheobronchopneumonitis, which involves the lower airway.

Most children who have spasmodic croup or acute laryngotracheitis do not require intubation or direct visualization of the airway. However, for a child whose illness is severe, who has signs of epiglottitis, or whose condition fails to follow the benign course of viral croup, direct airway visualization may be necessary. There is general agreement that the patient in whom complete obstruction of the airway is imminent requires laryngoscopy and intubation in a well-controlled environment.

Treatment

Mist Treatment

The mainstay of treatment for children who have croup is airway management. Since the 19th century, mist treatment has been used to treat croup symptoms. Cool mist is as effective as hot steam, and it avoids the risk of burns from hot water. Cool mist moistens airway secretions and soothes inflamed mucosa. Also, the humidity decreases the viscosity of tracheal mucus secretions. Animal studies have shown that the mist may activate mechanoreceptors in the larynx that produce a reflex slowing of respiratory flow rate. Young children best tolerate cool mist vapor delivered by aerosol while sitting on the parent's lap. Although cool mist is viewed as a safe and simple method to relieve croup symptoms, the humidity can intensify bronchospasm in children who have croup with wheezing due to laryngotracheobronchitis or pneumonitis. These children should have a trial of cool mist that is discontinued if the wheezing continues or worsens.

Epinephrine

Often croup requires no other treatment beyond mist therapy, but occasionally pharmacotherapy also is necessary. Nebulized epinephrine has been used to treat severe croup symptoms for almost 30 years and has made tracheotomy for croup virtually nonexistent. The initial studies performed in 1971 at Primary Children's Hospital in Salt Lake City, Utah, by Adair et al used racemic epinephrine administered by intermittent positive pressure. Subsequent studies demonstrated that racemic epinephrine is equally effective when administered by simple nebulization, which now is the usual route of administration.

Racemic epinephrine is a 1:1 mixture of the *d*- and *l*-isomers of epinephrine. The mechanism of action is believed to be stimulation of alpha-adrenergic receptors

with subsequent constriction of capillary arterioles. This results in fluid resorption instead of capillary leakage from the interstitial space and a consequent decrease in laryngeal mucosal edema. Additional studies have shown that equal doses of only the *l*-isomer of epinephrine have the same beneficial effects as the racemic form. This information is especially important outside the United States, where racemic epinephrine is not readily available.

Although nebulized epinephrine may have a dramatic effect on croup symptoms, decreasing inspiratory stridor and intercostal retractions, common adverse reactions to both the racemic and *l*-isomer forms, including tachycardia and hypertension, may limit their utility. In addition, the effect of the medication is brief (≤ 2 h), and as its activity diminishes, symptoms of croup can reappear (rebound phenomenon). Administration of nebulized epinephrine to children who had croup in the emergency department frequently led to hospital admission in the 1980s because of concern about the rebound phenomenon. Recent review and assessment of those recommendations suggest that it is safe to dismiss a child who has received nebulized epinephrine for croup from the emergency department after 3 to 4 hours of observation if the child has:

- No stridor at rest
- Normal air entry
- Normal color
- Normal level of consciousness
- Received one dose of 0.6 mg/kg dexamethasone orally or intramuscularly

Nebulized epinephrine should be reserved for children who are severely ill with croup, those needing intubation, those who have respiratory compromise in conjunction with retractions, and those whose stridor does not respond to cool mist therapy. A dose of 0.25 to 0.75 mL of 2.25% racemic epinephrine solution in 2.5 mL of normal saline can be given via nebulizer as often as every 20 minutes. If racemic epinephrine is not available, a 5-mL mixture of *l*-isomer epinephrine and saline (1:100) may be used. Nebulized epinephrine, however, should be used cautiously in patients who have tachycardia, a heart condition such as tetralogy of Fallot, or ventricular outlet obstruction because of possible adverse effects.

Corticosteroids

Corticosteroids decrease edema of the laryngeal mucosa via their anti-inflammatory action. After decades of debate about the potential benefits of systemic corticosteroids in children who have laryngotracheitis, there is now ample evidence to support their use. Clinical trials have

demonstrated clear improvement in children who have viral laryngotracheitis of mild-to-moderate severity treated with oral or parenteral steroids compared with those who received placebo. Clinical improvement, however, is usually not apparent until 6 hours after initiation of treatment. Different doses and routes of administration for corticosteroids have been proposed.

Dexamethasone has been evaluated extensively in published studies and is the steroid most used for croup. Initial studies showed the greatest improvement in children who received a single parenterally administered dose of 0.6 mg/kg of dexamethasone (maximal dose, 10 mg). However, further studies have shown that a single dose of dexamethasone 0.15 mg/kg is as effective as 0.3 or 0.6 mg/kg in relieving symptoms of viral laryngotracheitis of mild-to-moderate severity. Both oral and intramuscular routes of administration have been used in clinical trials and found to cause significant improvement compared with placebo. However, no study to date directly compares the efficacy of oral versus parenteral corticosteroids.

Corticosteroid treatment is generally well tolerated. One case of *Candida* laryngotracheitis complicating systemic steroid use in a child who had viral croup has been reported. A 14-month-old infant developed *C albicans* laryngotracheitis after receiving antibiotics and systemic corticosteroids at a dose of 1 mg/kg per day for 8 days to treat viral croup. Of note, steroids should be used very cautiously in patients who have more extensive disease involving the lower respiratory tract, such as laryngotracheobronchitis or laryngotracheobronchopneumonitis.

Currently, in the United States, inhaled corticosteroids do not have a clear role in the management of croup. Studies with budesonide, a nebulized corticosteroid, have shown it to be as effective as oral dexamethasone in relieving symptoms in children who have moderate-to-severe croup. The beneficial effect of nebulized budesonide occurred more rapidly (2 to 4 h) than that seen with systemic steroids. This effect may be due to local vasoconstriction in the edematous laryngeal mucosa. This medication, however, is not yet available in the United States, and data are not sufficient with other steroids administered via this route. One study documented a more rapid improvement of symptoms with nebulized dexamethasone than with placebo, but its use did not decrease the hospitalization rate significantly. In addition, some patients in the treatment group developed bacterial tracheitis. More data are required to define the role of nebulized budesonide versus systemic dexamethasone in the management of viral croup based

on clinical outcome, side effects, onset of action, and cost-effectiveness.

Endotracheal Intubation

Endotracheal intubation may be required for patients who have severe croup that does not respond to the previously cited therapies. Endotracheal intubation has replaced tracheotomy in the management of severe airway obstruction due to viral laryngotracheitis. The decision to intubate is based on clinical criteria that indicate hypercarbia and impending respiratory failure, including increasing stridor, respiratory rate, heart rate, retractions, the appearance of cyanosis, exhaustion, or change in mental status. Intubation usually is necessary only for a brief period until laryngeal edema resolves.

Helium–Oxygen Mixture

A mixture of helium and oxygen has been used at some medical centers to help treat viral croup. Helium is an inert, nontoxic gas that has low density and viscosity. These properties help it move through the obstructed airways more easily, improving laminar gas flow and decreasing the mechanical work of respiratory muscles. When combined with oxygen, the resulting gas improves blood oxygenation. Patients who have severe croup and breathe this mixture of helium and oxygen become more comfortable and may not require intubation.

Antibiotics

Antibiotics are reserved for patients who have evidence of laryngotracheobronchitis or laryngotracheobronchopneumonitis, which have a bacterial disease component. Such patients need to be treated empirically after appropriate cultures have been obtained. Therapy should be directed against *S aureus*, *S pyogenes*, *S pneumoniae*, and *H influenzae*. Initial treatment with a second-generation cephalosporin alone (eg, cefuroxime) or combination therapy with a semisynthetic penicillin, such as nafcillin or oxacillin, and a third-generation cephalosporin is reasonable.

Spasmodic croup is treated the same way as acute laryngotracheitis and usually requires nothing more than mist therapy.

Conclusion

The croup syndrome encompasses a group of diseases, of which acute laryngotracheitis is the most common and often is referred to as “viral croup.” In most cases, young children who have this illness do well with reassurance and cool mist, although more aggressive treatment may be necessary in some cases. However, adequate management requires awareness of the other diseases included in the croup syndrome—spasmodic croup, laryngotracheobronchitis, and laryngotracheobronchopneumonitis—as well as epiglottitis.

In general, laryngotracheitis is a benign disease. Few studies have shown a higher prevalence of subsequent increased bronchial reactivity in children who have a history of croup. This finding, however, like many other retrospective analyses concerning cause and effect of children who have reactive airways, is debatable. At present, acute laryngotracheitis is not preventable, but widespread use of influenza vaccine could reduce the incidence of croup due to influenza A and B.

Suggested Reading

- Asher MI. Infections of the upper respiratory tract. In: Taussig LM, Landau LI, eds. *Pediatric Respiratory Medicine*. 1st ed. St. Louis, MO: Mosby; 1999:530–547
- Baugh R, Gilmore BB Jr. Infectious croup: a critical review. *Otolaryngol Head Neck Surg*. 1986;95:40–46
- Cherry JD. Croup. In: Feigin RD, Cherry JD, eds. *Textbook of Pediatric Infectious Disease*. 4th ed. Philadelphia, Pa: WB Saunders; 1998:228–241
- Cressman WR, Myer CM III. Diagnosis and management of croup and epiglottitis. *Pediatr Clin North Am*. 1994;41:265–276
- Johnson DW, Schuh S, Koren G, Jaffe DM. Outpatient treatment of croup with nebulized dexamethasone. *Arch Pediatr Adolesc Med*. 1996;150:349–355
- Kaditis AG, Wald ER. Viral croup: current diagnosis and treatment. *Pediatr Infect Dis J*. 1998;17:827–834
- Rosekrans JA. Viral croup: current diagnosis and treatment. *Mayo Clin Proc*. 1998;73:1102–1107
- Wald E. Croup. In: McMillan JA, DeAngelis CD, Feigin RD, Warshaw JB, eds. *Oski's Pediatrics Principles and Practices*. 3rd ed. Philadelphia, Pa: Lippincott Williams & Wilkins; 1999: 1307–1311

PIR Quiz

Quiz also available online at www.pedsinreview.org.

1. Viral croup occurs primarily in the late fall and winter. Parainfluenza viruses (types 1, 2, 3) are the most frequent viral pathogens (>65% of cases). Which of the following viruses would be most likely to cause episodes of severe laryngotracheitis?
 - A. Adenovirus.
 - B. Influenza A virus.
 - C. Measles virus.
 - D. Parainfluenza virus.
 - E. Respiratory syncytial virus.
2. A 2-year-old boy who has been well except for mild rhinorrhea awakens suddenly at night with dyspnea, croupy cough, and moderate inspiratory stridor. He is afebrile, and these symptoms abate following the administration of moist air. Which of the following findings would be *most* consistent with acute spasmodic croup?
 - A. Cherry-red color and swelling of the epiglottis.
 - B. Diffuse erythema of the laryngeal mucosa.
 - C. Firmly adherent exudative membranes in the posterior pharyngeal and laryngeal areas.
 - D. Marked facial swelling associated with laryngeal edema.
 - E. Pale, boggy appearance of the laryngeal mucosa.
3. A previously healthy 4-year-old girl is transported via ambulance because of a rapid onset of severe respiratory distress. In the emergency department, she appears toxic and very anxious. She is drooling and prefers to sit forward. The girl recently immigrated to this country and has had little health care; her grandparents are unsure if she has received any immunizations to date. Of the following, these findings are *most* consistent with the diagnosis of:
 - A. Acute angioneurotic edema.
 - B. Bacterial tracheitis.
 - C. Epiglottitis.
 - D. Laryngotracheobronchitis.
 - E. Retropharyngeal abscess.
4. In addition to mist therapy, nebulized epinephrine has been used to treat croup symptoms. Administration of nebulized epinephrine can result in fluid resorption (instead of capillary leakage) and decreased laryngeal mucosal edema, with subsequent improved inspiratory stridor and intercostal retractions. The adverse effect of nebulized epinephrine that is *most* likely to limit the usefulness of this drug in a child who has tetralogy of Fallot and severe croup is:
 - A. Bacterial tracheitis.
 - B. Bronchospasm.
 - C. *Candida albicans* laryngotracheitis.
 - D. Hypotension.
 - E. Tachycardia.